The American Journal of Surgical Pathology *27(3): 311–324, 2003* 

# Pulmonary Carcinomas With Pleomorphic, Sarcomatoid, or Sarcomatous Elements

## A Clinicopathologic and Immunohistochemical Study of 75 Cases

Giulio Rossi, M.D., Alberto Cavazza, M.D., Nathalie Sturm, M.D., Mario Migaldi, M.D., Ph.D., Nicola Facciolongo, M.D., Lucia Longo, M.D., Antonio Maiorana, M.D., and Elisabeth Brambilla, M.D.

We collected 75 primary pulmonary carcinomas with pleomorphic, sarcomatoid, or sarcomatous elements to better define their clinical, histologic, and immunohistochemical profile. The patient's age ranged from 42 to 81 years (mean 65 years), and the male-to-female ratio was 9.7:1. Sixty-nine patients (92%) were smokers. Cough and hemoptysis were the most frequent presenting symptoms. Fifty-nine patients (65%) died of disease: only stage significantly predicts overall survival ($p = 0.0273$). Microscopically, based on the WHO criteria, 58 cases were classified as pleomorphic carcinoma (51 with an epithelial component, 7 composed exclusively of spindle and giant cells), 10 as spindle cell carcinoma, 3 as giant cell carcinoma, 3 as carcinosarcoma, and 1 as pulmonary blastoma. Immunohistochemically, in the tumors composed exclusively of spindle and/or giant cells, thyroid transcription factor-1 (TTF-1) and cytokeratin 7 were positive in 55% and 70% of the cases, respectively, whereas surfactant protein-A was always negative. In pleomorphic carcinomas with an epithelial component, cytokeratin 7, TTF-1, and surfactant protein-A were positive in the sarcomatoid component in 62.7%, 43.1%, and 5.9% of the cases, respectively, whereas they were always negative in the sarcomatous part of carcinosarcomas and blastoma. In the epithelial component of pleomorphic carcinomas, cytokeratin 7, TTF-1, and surfactant protein-A were positive in 76.4%, 58.8%, and 39.2% of the cases, respectively, whereas the same antibodies did not react with the epithelial component of carcinosarcomas; in the case of blastoma, the epithelial part of the tumor was positive for cytokeratin 7 and TTF-1, whereas it was negative for surfactant protein-A. Cytokeratin 20 was always negative. In our opinion, this study: 1) supports the metaplastic histogenetic theory for this group of tumors; 2) shows that cytokeratin 7 and TTF-1, but not surfactant protein-A, are useful immunohistochemical markers in this setting; 3) confirms that stage is at the moment the only significant prognostic parameter, as in conventional non-small cell lung carcinomas; and 4) shows that this group of tumors has a worse prognosis than conventional non-small cell lung carcinoma at surgically curable stages I, justifying their segregation as an independent histologic type in the WHO classification.
**Key Words:** Lung—Pleomorphic carcinoma—TTF-1—Cytokeratins—Immunohistochemistry.

*Am J Surg Pathol 27(3): 311–324, 2003.*

The recent World Health Organization (WHO) classification of lung tumors unified the heterogeneous group of non-small cell lung carcinomas (NSCLC) that contain a sarcoma or sarcoma-like component under the designation "carcinomas with pleomorphic, sarcomatoid, or sarcomatous elements" (CPSS).[8,71,72] This group includes different entities, such as pleomorphic carcinoma (PC), spindle cell carcinoma (SCC), giant cell carcinoma (GCC), carcinosarcoma (CS), and pulmonary blastoma (PB).[8,71,72] Globally, these tumors are rare, comprising approximately 0.1–0.4% of all lung malignancies.[8,71,73] They predominantly occur in heavily smoking males, with an average age at diagnosis of 60 years, and they pursue an aggressive clinical course.[10,19,21,29,31,37,41,42,48,49,59,61,64,67,75–77]

Histologically, CPSS commonly appear as biphasic neoplasms, with a carcinoma (e.g., adenocarcinoma, squamous cell carcinoma, large cell carcinoma, or a mixture of these) intermingled with a sarcomatoid (spindle and/or giant cell) component, or with heterologous sarcomatous tissue. More rarely, they are devoid of an ob-

From the Section of Pathology (G.R., M.M., A.M.), University of Modena and Reggio Emilia; the Operative Units of Pathology (A.C.) and Respiratory Diseases (N.F.), S. Maria Nuova Hospital, Reggio Emilia; the Division of Oncology (L.L.), Hospital of Faenza, AUSL Ravenna, Italy; and the Laboratory of Cellular Pathology (N.S., E.B.), CHU of Grenoble, France.

Supported by the Ministero dell' Istruzione, dell' Università e della Ricerca (MIUR), Rome, Italy.

Address correspondence and reprint requests to Giulio Rossi, MD, Department of Pathological Anatomy and Forensic Medicine, Section of Pathology, University of Modena and Reggio Emilia, Via del Pozzo, 71-41100 Modena, Italy; e-mail: rossi.giulio@unimo.it

vious epithelial differentiation on routine microscopy, and they consist of a pure sarcomatoid component.

The differential diagnosis with a primary or metastatic sarcoma may be difficult on hematoxylin and eosin staining, particularly when an obvious carcinomatous component is lacking. Antibodies against epithelial markers, such as cytokeratins and epithelial membrane antigen, together with an extensive tumor sampling, are very helpful in this setting.[1,4,7,9,10,14,15,19,21,25,29,31,41,42,48,49,55,58,59,67,74–77] However, the same antibodies have no value in differentiating a pulmonary CPSS from a similar neoplasm arising in another organ.[7,22,77]

Nowadays, several monoclonal antibodies are available to evaluate the pulmonary origin of a tumor, particularly thyroid transcription factor-1 (TTF-1), surfactant apoprotein-A (SP-A), and the coordinated expression of cytokeratins 7 (CK7) and 20 (CK20). TTF-1 is a 38-kDa homeodomain-containing transcription protein of the Nkx2 gene family that regulates the pulmonary epithelial morphogenesis and the development of thyroid gland and diencephalon. It is a specific immunohistochemical marker for thyroid and pulmonary tumors, particularly for adenocarcinoma and small cell carcinoma.[2,5,11,17,20,24,33,36,52,53,57,62] SP-A is a monoclonal antibody that recognizes 34–37-kDa and 62-kDa human surfactant apoproteins, mainly located in normal and hyperplastic type II pneumocytes and playing an essential role in avoiding alveolar collapse at the end of expiration. SP-A is mainly expressed in pulmonary adenocarcinoma.[6,11,35,51,62] CK7, a 54-kDa basic protein, is strongly expressed in different epithelia, including breast, endometrium, bladder, pancreas and biliary tract, stomach, and lung,[11–13,39,40,56] whereas CK20, a 46-kDa acid protein, is basically located in the epithelium of intestine, bladder, pancreas, and biliary tract.[12,13,39,40,44,45]

TTF-1, SP-A, CK7, and CK20 are commonly used in differentiating a primary pulmonary carcinoma from a metastasis. However, to our knowledge, these antibodies have never been assessed in CPSS.

The aims of this study are to analyze the clinical and histologic features of a relatively large series of surgically treated pulmonary CPSS and to investigate the immunohistochemical expression of TTF-1, SP-A, CK7, and CK20 in this group of tumors.

## MATERIALS AND METHODS

The files of the Department of Pathology of the University of Modena and Reggio Emilia, and of the Operative Unit of Pathology of the S. Maria Nuova Hospital of Reggio Emilia, were searched for surgical cases of pulmonary carcinoma in which a spindle and/or giant cell component was reported. Among 5788 lung carcinomas diagnosed from 1984 to 2001, a total of 86 cases were selected. After histologic and immunohistochemical review, two cases were reinterpreted as monophasic synovial sarcomas and four as metastatic neoplasms (two leiomyosarcomas from the uterus, one malignant fibrous histiocytoma from the retroperitoneum, and one spindle cell thymoma). Five cases were excluded lacking of complete clinical information. Thus, 75 cases were selected for this study. All the cases consisted of surgical resection specimens, and the tissue was routinely formalin fixed and paraffin embedded. A mean of 6.5 (range 3–11) hematoxylin and eosin-stained slides for tumor was available. All the slides were reviewed at a multiheaded microscope by two pathologists (G.R., A.C.). The cases were included in the study if they fulfill one of the following histologic criteria: 1) presence of at least 10% of sarcomatoid (malignant spindle and/or giant cells) or true sarcomatous (malignant chondroid, osteoid, or muscular) component in an otherwise conventional NSCLC; and 2) immunoreactivity for at least one broad-spectrum epithelial marker (MNF 116, CAM 5.2, AE1/AE3, or epithelial membrane antigen) in a monophasic malignant spindle and/or giant cell neoplasm.

The tumors were classified according to the criteria of the WHO classification.[8,71,72] Briefly, PC is defined as an NSCLC combined with neoplastic spindle and/or giant cells or a carcinoma consisting only of spindle and giant cells. SCC is a carcinoma composed exclusively of spindle-shaped tumor cells, whereas GCC is composed only of neoplastic, highly pleomorphic giant cells. In CS a carcinoma component is combined with a sarcoma, the latter consisting of heterologous elements, such as malignant cartilage, bone, or muscle. PB is a biphasic tumor in which both the epithelial and the mesenchymal components have a primitive, "fetal-type" appearance.

The extent of necrosis was estimated by light microscopy, as follows: 0, no necrosis; 1+, small foci of necrosis; 2+, geographic necrosis; 3+, massive necrosis occupying >50% of the neoplasm. Finally, the presence of vascular invasion was recorded.

For immunohistochemical analysis, the following antibodies were used: CK7 (clone OV-TL 12/30, Dako, Glostrup, Denmark; 1:100 dilution), CK20 (clone Ks 20.8, Dako; 1:100 dilution), TTF-1 (clone 8G7G3/1; Dako, Glostrup, Denmark; 1:100 dilution), and SP-A (clone PE-10; Medite, Milan, Italy; 1:200 dilution). In each case 4-μm-thick sections were obtained from a representative block. Sections were air-dried overnight at 37°C, then deparaffinized in xylene and rehydrated through a decreasing concentration of alcohol to water. Endogenous peroxidase activity was blocked by immersion for 10 minutes with 3% hydrogen peroxide ($H_2O_2$) in methanol. Sections stained with CK7 and CK20 were digested in 0.01% protease solution in 0.005 M (pH 7.6) Tris-buffered saline at 37°C for 15 minutes. For TTF-1 a

microwave antigen retrieving was performed for 30 minutes in 0.01 M citrate buffer (pH 7.8). Antigen retrieval was not used for SP-A. Incubation with the primary antibodies was accomplished with a modified avidin-biotin peroxidase technique using a commercial immunohistochemical autostainer (Ventana, Strasbourg, France); 3′3-diaminobenzidene was used as the chromogene and Harris hematoxylin as the counterstain. Alveolar type II cells served as positive internal controls for TTF-1, CK7, and SP-A, whereas appropriate sections of a colonic adenocarcinoma were used as positive control for CK20. Negative controls were included in each test by substituting the primary antibodies with nonimmune mouse IgG.

For each antibody the percentage of positive cells (0, negative; 1+, 1–25%; 2+, 26–50%; 3+, >50%) and the intensity of staining (0, negative; 1, weak; 2, moderate; 3, strong) were recorded. A tumor was considered positive if >10% of the neoplastic cells reacted with an intensity of ≥2+, on the relevant subcellular localization (nuclear for TTF-1, cytoplasmic for others).

Clinical data were collected from pathologic reports, from clinical charts, from referring physicians, or directly from the patient's families. The following data were recorded: age, sex, smoking habit, presenting clinical symptoms, tumor size, location, stage, and follow-up (calculated from the date of surgery). Staging was evaluated according to the International Union Against Cancer criteria.[63]

The correlation between clinicopathologic and immunohistochemical variables was performed using contingency table methods and tested for significance using the Pearson's $\chi^2$ test. Survival curves were evaluated using the Kaplan-Meier method and statistical significance was estimated with the log-rank test. Univariate and multivariate relative risk were calculated using Cox proportional hazards regression (SPSS version 10.0, Chicago, IL, USA). A difference with probability (p) values ≤0.05 was considered significant.

## RESULTS

The most relevant clinical and pathologic data are summarized in Table 1.

### Clinical Findings

The patients consisted of 68 males and 7 females (male/female ratio, 9.7:1). The mean age at diagnosis was 65 ± 8.4 years, with a wide range (42–81 years). Sixty-nine patients (92%) were smokers. A simple lobectomy plus regional lymph node sampling was performed in 61 cases (81.3%), and a pneumonectomy was performed in 14 (18.7%) cases. No patient underwent preoperative adjuvant radiotherapy or chemotherapy. In 46 cases (61.3%), the tumor arose in the right lung, whereas the left lung was involved in the remaining 29 cases. In 36 patients (48%), the tumor had a predilection for the upper lobes (25 cases in the right side, 11 in the left). The neoplasm was peripheral in 53 cases (70.7%) and central in 13 (17.3%); in the remaining 9 cases, the lesion was so large that the exact location could not be evaluated.

Cough and/or hemoptysis were the most common presenting symptoms, occurring in 60 patients (80%), and fever, dyspnea, and chest pain represented the other clinical manifestations. In five patients (6.7%), the tumor was an incidental finding.

Forty-three patients (57.3%) were considered in pathologic stage I (9 Ia, 34 Ib), 20 (26.7%) in stage II (7 IIa, 13 IIb), and 12 (16%) in stage III (11 IIIa, 1 IIIb).

### Follow-up and Prognosis

Follow-up was obtained in every case. Forty-nine patients (65.3%) died of disease, with a follow-up ranging from 1 to 145 months. Globally, the median survival was 19 months (mean 29.28 ± 31.16 months). A median survival of 31 months was observed in stage I, whereas 10.5 and 9 months, respectively, were the median survival in stage II and III. Twenty patients (26.7%) were alive and free of disease, with a follow-up ranging from 2 to 156 months. Sixteen of these patients were in pathologic stage I, and four in stage II. Six patients (8%) were alive with disease progression.

Patients with pathologic stage I had a statistically significant better prognosis than patients with stage II and III ($p = 0.0273$) (Fig. 1). No significant differences in overall survival were observed with other parameters, such as tumor size >5 cm, pure spindle and/or giant cell histotype, extension of necrosis, immunohistochemical results, sex, and peripheral or central site of the tumor.

When a Cox proportional hazards model was constructed, including age at diagnosis, sex, histotypes, immunohistochemical results, extension of necrosis, and tumor location, only stage (I or > I) predicted the overall survival ($p = 0.0107$).

### Pathologic Findings

Macroscopically, tumors were generally poorly circumscribed, gray–whitish with large, yellowish necrotic areas and hemorrhagic foci. The size ranged from 1 to 13 cm, with a median of 4.9 cm (± 2.65 cm).

Histologically, 10 cases (13.3%) were classified as SSC, 3 (4%) as GCC, 58 (77.3%) as PC, 3 (4%) as CS, and 1 (1.3%) as PB.

SCCs were characterized by a variety of growth patterns. In two cases neoplastic cells were cigar-shaped and arranged in long fascicles, simulating a leiomyosarcoma (Fig. 2A). In three cases tumor cells were more elon-

**TABLE 1.** *Summary of relevant clinical and pathologic findings: part 1*

| Case | Age (yrs) | Sex | Complaints | Size (cm) | Site | Histotype | Stage | Outcome (months) |
|---|---|---|---|---|---|---|---|---|
| 1 | 57 | M | C+H | 1.8 | LUL | SCC | 1a | A (40) |
| 2 | 62 | M | C+H | 6.0 | LUL | SCC | 1b | D (32) |
| 3 | 70 | M | F | 5.0 | RUL | SCC | 1b | D (53) |
| 4 | 74 | M | H | 5.0 | LUL | SCC | 1b | D (18) |
| 5 | 73 | M | C | 1.5 | RIL | SCC | 1b | A (19) |
| 6 | 54 | M | H | 1.5 | RUL | SCC | 2b | AWD (22) |
| 7 | 64 | M | C+H | 2.0 | RUL | SCC | 1a | D (13) |
| 8 | 57 | M | C+H | 4.5 | LUL | SCC | 2b | A (10) |
| 9 | 48 | M | H | 5.0 | RL | SCC | 3a | D (8) |
| 10 | 45 | M | C+H | 5.5 | RL | SCC | 2b | AWD (11) |
| 11 | 71 | M | H | 3.5 | RL | GCC | 3a | D (34) |
| 12 | 67 | M | C+H | 12.0 | RUL | GCC | 1b | D (22) |
| 13 | 47 | M | H | 4.5 | LL | GCC | 1b | A (2) |
| 14 | 70 | M | C | 4.0 | RUL | PC (GCC/SCC) | 1b | D (32) |
| 15 | 62 | M | ChP | 10.0 | LIL | PC (GCC/SCC) | 1b | D (1) |
| 16 | 61 | M | C+H | 5.5 | RUL | PC (GCC/SCC) | 1b | D (38) |
| 17 | 58 | M | H | 1.0 | RUL | PC (GCC/SCC) | 1a | A (118) |
| 18 | 70 | F | H | 4.0 | RUL | PC (GCC/SCC) | 1b | D (9) |
| 19 | 58 | F | Inc | 2.0 | LUL | PC (GCC/SCC) | 1b | D (10) |
| 20 | 57 | M | C+H | 6.0 | RIL | PC (GCC/SCC) | 2b | AWD (19) |
| 21 | 68 | M | C+H | 13.0 | LIL | PC (LCC+GCC) | 2b | D (2) |
| 22 | 57 | M | C | 3.5 | RUL | PC (LCC+GCC) | 1b | D (41) |
| 23 | 72 | M | ChP | 8.0 | RIL | PC (LCC+GCC) | 3a | D (2) |
| 24 | 42 | M | C+H | 5.5 | LL | PC (LCC+GCC) | 2b | D (48) |
| 25 | 62 | M | H | 6.0 | RUL | PC (LCC+GCC) | 3a | AWD (71) |
| 26 | 72 | M | Inc | 3.5 | RUL | PC (LCC+GCC) | 1b | D (17) |
| 27 | 69 | M | C | 3.5 | LL | PC (LCC+SCC) | 3b | D (8) |
| 28 | 55 | M | Inc | 4.0 | LL | PC (LCC/SCC) | 3a | D (2) |
| 29 | 67 | M | C | 2.4 | LUL | PC (LCC+SCC) | 1b | A (15) |
| 30 | 69 | F | C+H | 5.0 | LIL | PC (LCC+GCC/SCC) | 2a | A (80) |
| 31 | 81 | M | Inc | 3.4 | RIL | PC (LCC+GCC/SCC) | 1b | A (156) |
| 32 | 62 | M | F | 2.0 | LUL | PC (LCC+GCC/SCC) | 1a | D (45) |
| 33 | 54 | M | H | 7.0 | RUL | PC (LCC+GCC/SCC) | 1b | A (88) |
| 34 | 51 | M | ChP | 8.0 | LUL | PC (LCC+GCC/SCC) | 2b | D (58) |
| 35 | 72 | M | C | 10.0 | RUL | PC (LCC+GCC/SCC) | 1b | D (8) |
| 36 | 70 | M | C+H | 8.0 | RL | PC (LCC+GCC/SCC) | 2b | D (16) |
| 37 | 60 | M | H | 1.0 | LIL | PC (LCC+GCC/SCC) | 1a | D (55) |
| 38 | 61 | M | C | 4.0 | LIL | PC (LCC+GCC/SCC) | 1b | A (145) |
| 39 | 72 | M | C | 3.5 | RIL | PC (LCC/ADC+GCC) | 1b | D (46) |
| 40 | 66 | M | H | 7.0 | RUL | PC (LCC/ADC+GCC/SCC) | 2a | D (8) |
| 41 | 65 | M | Dys | 3.5 | RUL | PC (LCC/ADC+GCC/SCC) | 1b | D (35) |
| 42 | 51 | M | H | 8.0 | LUL | PC (LCC/ADC+GCC/SCC) | 2b | D (3) |

gated, with moderately atypical nuclei, and grew in long fascicles with a vague herringbone pattern, giving a striking resemblance to fibrosarcoma (Fig. 2B). An appreciable number of lymphocytes, plasma cells, and eosinophils intermingled with relatively uniform spindle elements was observed in four cases: such tumors mimicked an inflammatory pseudotumor or a follicular dendritic cell sarcoma (Fig. 2C). Finally, in one case atypical spindle cells dissected the alveolar septa and were associated with extravasated erythrocytes, superficially simulating an angiosarcoma (Fig. 2D).

Three neoplasms were classified as pure GCCs. Two of these tumors consisted of pleomorphic cells with abundant, eosinophilic cytoplasm and multiple or single highly atypical nuclei with prominent nucleoli. Neoplastic cells were often loosely arranged in an inflammatory-rich stroma and showed prominent emperipolesis (Fig. 3A). Large necrotic and hemorrhagic areas were always present. In one case many syncytiotrophoblast-like giant cells associated with hemorrhagic foci were observed, giving to the lesion a choriocarcinoma-like appearance (Fig. 3B).

Fifty-eight cases were classified as PC. In 51 cases a carcinomatous component was present (Fig. 4). It consisted of squamous cell carcinoma (SqC) in 12 cases, adenocarcinoma (ADC) in 14, large cell carcinoma (LCC) in 18, mixed adenocarcinoma/large cell carcinoma (ADC/LCC) in 5, and adenosquamous carcinoma (ADC/SqC) in 2. In one case the LCC component showed a rhabdoid phenotype. The sarcomatous component consisted only of spindle cells in 15 cases, only of giant cells in 10, and of both spindle and giant cells in 26. Notably, a solely giant cell component was never found in association with SqC, whereas no significant differences were noticed in the distribution of the other histotypes.

**TABLE 1.** *Summary of relevant clinical and pathologic findings: part 2*

| Case no. | Age (y) | Sex | Complaints | Size (cm) | Site | Histotype | Stage | Outcome (mo) |
|---|---|---|---|---|---|---|---|---|
| 43 | 68 | M | F | 6.0 | LL | PC (ADC/SCC) | 3a | D (28) |
| 44 | 71 | M | H+F | 3.5 | LUL | PC (ADC+SCC) | 3a | D (1) |
| 45 | 71 | M | C | 1.5 | RIL | PC (ADC+SCC) | 1a | D (18) |
| 46 | 60 | M | H | 2.5 | RUL | PC (ADC+SCC) | 1a | A (23) |
| 47 | 67 | M | C | 5.0 | LIL | PC (ADC+SCC) | 3a | D (10) |
| 48 | 78 | M | F | 13.0 | LIL | PC (ADC+SCC) | 1b | D (2) |
| 49 | 65 | M | C+H | 4.0 | RML | PC (ADC+SCC) | 2a | D (3) |
| 50 | 72 | M | F | 3.0 | LUL | PC (ADC+SCC) | 1b | A (25) |
| 51 | 62 | M | H | 8.0 | LL | PC (ADC+GCC) | 2b | D (2) |
| 52 | 68 | M | H | 3.5 | RUL | PC (ADC+GCC) | 3a | D (26) |
| 53 | 55 | M | H | 4.6 | LIL | PC (ADC+GCC) | 2a | D (31) |
| 54 | 72 | M | C | 3.5 | RUL | PC (ADC+GCC/SCC) | 1b | A (44) |
| 55 | 67 | F | H | 5.0 | RML | PC (ADC+GCC/SCC) | 2b | A (2) |
| 56 | 65 | M | C+H | 4.5 | RUL | PC (ADC+GCC/SCC) | 2b | AWD (7) |
| 57 | 71 | F | C+H | 6.5 | RIL | PC (ADC+GCC/SCC) | 2a | A (72) |
| 58 | 70 | M | C+H | 5.0 | RIL | PC (SqC+SCC) | 3a | D (16) |
| 59 | 69 | M | C+H | 3.5 | RUL | PC (SqC+SCC) | 1b | A (41) |
| 60 | 73 | M | C+H | 1.5 | RUL | PC (SqC+SCC) | 1a | A (22) |
| 61 | 59 | F | C+H | 6.0 | RIL | PC (SqC+SCC) | 1b | AWD (18) |
| 62 | 60 | M | Inc | 7.5 | RML | PC (SqC+GCC/SCC) | 2a | D (8) |
| 63 | 70 | M | F | 3.5 | RIL | PC (SqC+GCC/SCC) | 1b | D (1) |
| 64 | 76 | M | H | 2.0 | RIL | PC (SqC+GCC/SCC) | 1a | A (76) |
| 65 | 63 | M | C+H | 5.0 | RIL | PC (SqC+GCC/SCC) | 1b | D (32) |
| 66 | 76 | M | C | 3.5 | RUL | PC (SqC+GCC/SCC) | 1b | A (54) |
| 67 | 76 | M | C | 4.0 | RUL | PC (SqC+GCC/SCC) | 1b | D (46) |
| 68 | 73 | M | C+H | 8.0 | RUL | PC (SqC+GCC/SCC) | 2b | D (8) |
| 69 | 77 | M | C+H | 3.5 | LIL | PC (SqC+GCC/SCC) | 1b | A (11) |
| 70 | 69 | M | C | 10.0 | RUL | PC (ADC/SqC+GCC/SCC) | 1b | D (7) |
| 71 | 50 | F | H | 3.5 | LIL | PC (ADC/SqC+GCC/SCC) | 1b | D (16) |
| 72 | 69 | M | C+H | 6.5 | LL | CS | 3a | D (8) |
| 73 | 76 | M | C+H | 3.5 | RUL | CS | 1b | D (19) |
| 74 | 65 | M | C+H | 4.0 | LUL | CS | 2a | D (11) |
| 75 | 69 | M | H | 3.5 | RUL | PB | 1b | D (45) |

C, cough; H, hemophtoe; F, fever; ChP, chest pain; Inc, incidental finding; Dys, dyspnea; RL, right lung; LL, left lung; RUL, right upper lobe; LUL, left upper lobe; RIL, right inferior lobe; LIL, left inferior lobe; RML, right middle lobe; PC, pleomorphic carcinoma; ADC, adenocarcinoma; SqC, squamous cell carcinoma; LCC, large cell carcinoma; GCC, giant cell carcinoma; SCC, spindle cell carcinoma; CS, carcinosarcoma; PB, pulmonary blastoma; A, alive and well; D, dead; AWD, alive with disease.

In seven PC a carcinomatous component was not evident on hematoxylin and eosin. These tumors simulated a pleomorphic malignant fibrous histiocytoma: they were composed of atypical fusiform elements arranged in a storiform pattern, admixed with bizarre multinucleated giant cells (Fig. 5). An inflammatory background was always present.

Finally, three CS were found (Fig. 6). The sarcomatous component was represented by cartilage (two cases) and bone (one case): the carcinomatous foci took the form of SqC in all cases. Finally, one case was characterized by an undifferentiated blastema-like component associated with a conventional ADC (Fig. 7): in agreement with Koss et al.[36], we classified this case as PB.

Overall, geographic and diffuse necrosis (2+ and 3+) was present in 19 (25.3%) and 50 cases (66.7%), respectively, whereas the remaining 6 cases (8%) presented punctated necrotic foci scattered throughout the tumor (1+). Vascular invasion was noted in 48 cases (64%). Notably, the latter finding was observed particularly in cases with a spindle cell component (9 of 10 SCC) (Fig. 8).

## Immunohistochemical Findings

Distribution and grading of immunoreactivity for TTF-1, CK7, and SP-A are summarized in Table 2.

## CK7

Tumors composed exclusively of spindle and/or giant cells showed a positive immunostaining in 14 cases of 20 (70%: 7 SCC, 2 GCC, and 5 PC), whereas the remaining 6 cases were negative. Strong immunoreactivity was observed in 6 of these 14 tumors (3 SCC, 1 GCC, and 2 PC), the others presenting a moderate intensity of staining (Fig. 9A, B). Globally, the carcinomatous component in PC reacted at least moderately with CK7 in 39 cases of 51 (76.4%), whereas spindle and/or giant cells showed a positive staining in 32 cases (62.7%): in tumors with a

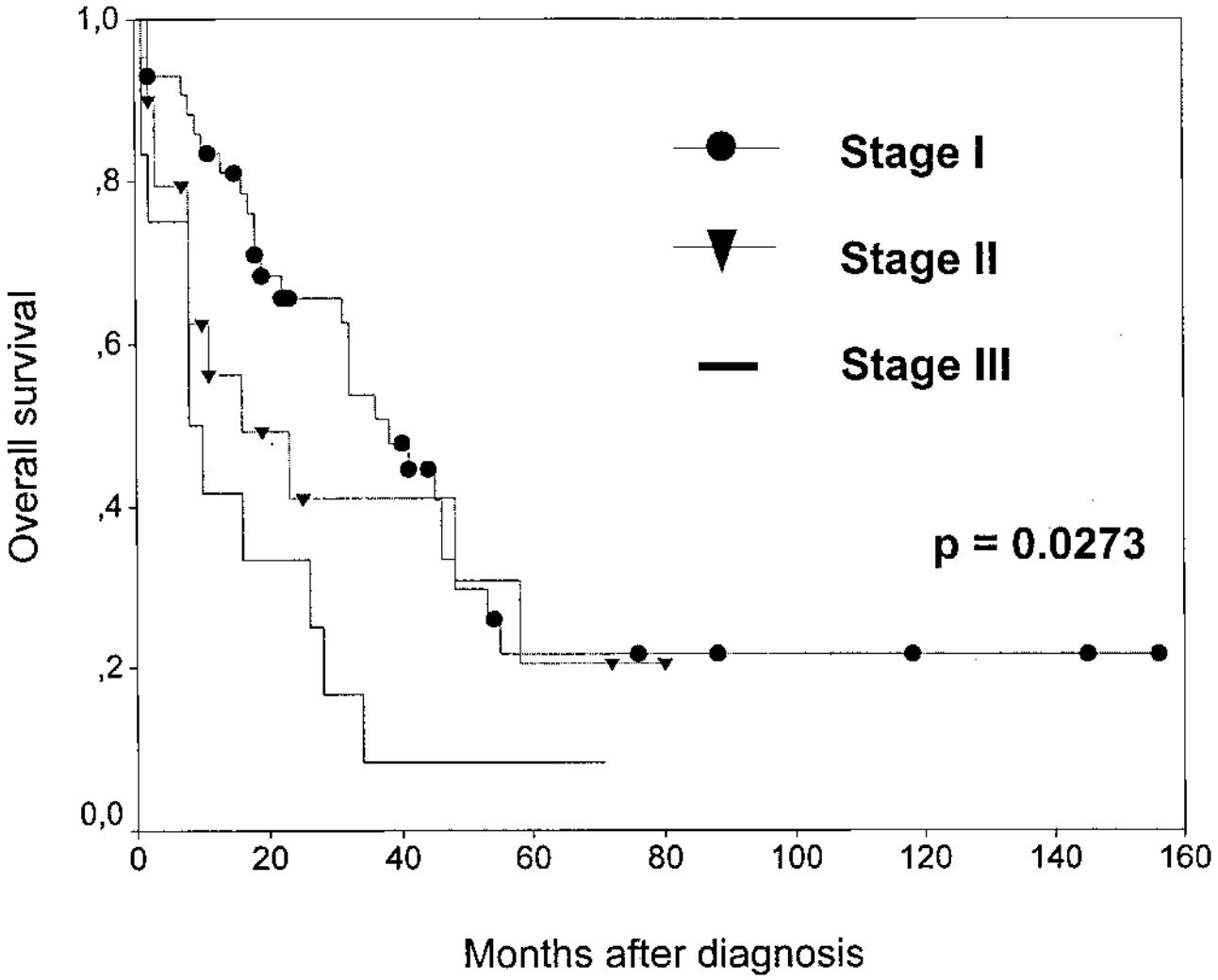


**FIG. 1.** Kaplan-Meier curve for overall survival in 75 patients who underwent surgery for carcinomas with pleomorphic, sarcomatous, and/or sarcomatoid components of the lung, stratified according to stage at diagnosis (p = 0.0273 by log-rank test).

negative epithelial component, the sarcomatoid cells were always negative. Positive staining for CK7 was noted in the epithelial component of all PC containing ADC (Fig. 9C), and their corresponding sarcomatoid component was positive in all but two cases (one spindle cell and one mixed spindle/giant cell). Five of 12 (41.6%) PC with a SqC component were weakly positive in the latter, but only two of these reacted in the sarcomatoid component. PC containing LCC expressed CK7 (in both components) in 13 of 18 cases (72.2%); notably, the case with rhabdoid features was negative. PC with an ADC/SqC epithelial component were immunoreactivity in one of two cases: in the positive case both components were reactive.

Finally, a moderate positivity was seen only in the ADC component of the PB (Fig. 9D), whereas the three CS were completely negative.

**TTF-1**

Positive nuclear immunostaining was observed in 11 of 20 (55%) pure spindle and/or GCCs (4 SCC, 2 GCC and 5 PC). Notably, none of these neoplasms contained >50% of immunoreactive cells (Fig. 10A, B).

Carcinomatous component in PC showed immunoreactivity for TTF-1 in 30 cases of 51 (58.8%), namely, in 12 of 14 ADC, in 13 of 18 LCC, in 4 of 5 ADC/LCC, in 1 of 2 ADC/SqC, and in no SqC. Again, no tumor with a negative epithelial component had positive sarcomatoid cells.

In only three PC with an ADC epithelial component, the associated malignant spindle cells did not react for TTF-1, the remaining 11 cases displaying the same positive immunophenotype in both components (Fig. 10C). At least moderate expression was reported in the spindle

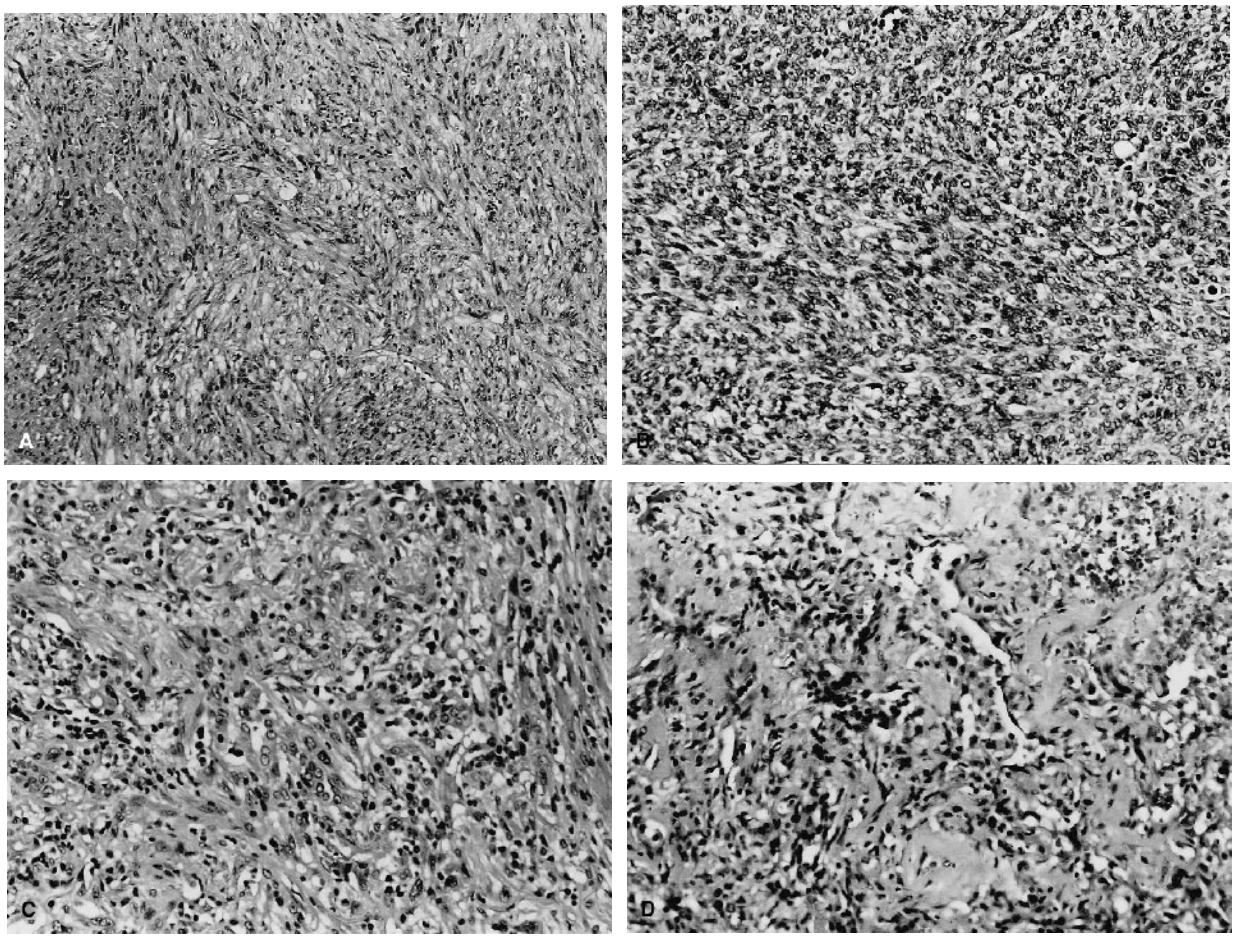


**FIG. 2.** Spindle cell carcinoma appears as a leiomyosarcoma-like proliferation of long fascicles of cigar-shaped cells **(A)**, or consists of a fibrosarcoma-like neoplatic growth arranged in a herringbone pattern **(B)**, or mimics an inflammatory pseudotumor with uniform bland neoplastic elements intermingled with a collagenized and lymphoid-rich stroma **(C)**. Malignant spindle cells dissecting alveolar septa in a hemorrhagic background strikingly resemble an angiosarcoma **(D)**.

and/or giant elements in 7 of 18 PC associated with LCC, in 3 of 5 associated with ADC/LCC, in 1 of 2 associated with ADC/SqC, and in none of the cases admixed with SqC.

Both the epithelial and the heterologous tissues of CS did not react for TTF-1. Positive staining was observed in the ADC component of PB, but not in the blastematous tissue (Fig. 10D).

### SP-A

All carcinomas composed only of spindle and/or giant cells were negative (Fig. 11). Globally, among the 51 PC with an epithelial component, 20 (39.2%) were positive in the latter, especially in ADC (12 of 14). A moderate reactivity was found in the sarcomatoid component in only three PC associated with ADC (5.9%: one composed of spindle cells, one of giant cells, and one of spindle/giant cells). Spindle and/or giant elements in the remaining PC were completely negative.

Both the epithelial and the sarcomatous components of CS and PB were negative.

### CK20

As expected, CK20 did not react in any case, both in the epithelial and in the sarcomatoid/sarcomatous components.

## DISCUSSION

We collected a relatively large series of CPSS to better define their clinicopathologic and immunohistochemical profile. The recent WHO classification of lung tumors defines CPSS as "a group of poorly differentiated NSCLC that contain a component of sarcoma or sarcoma-like elements."[8,71,72] Under this heading several different entities are considered. PC is defined as "a poorly differentiated NSCLC, namely squamous cell carcinoma, adenocarcinoma or large cell carcinoma, con-

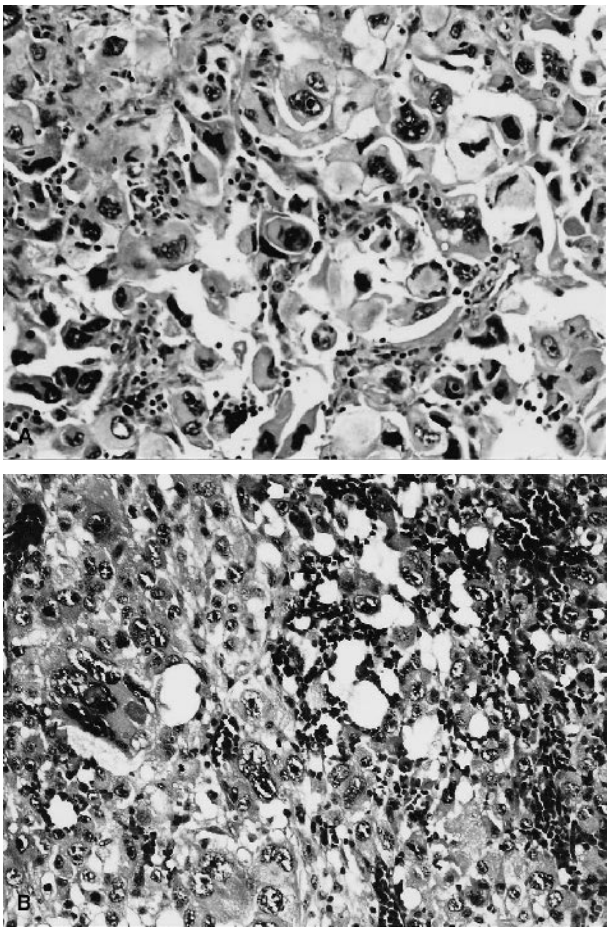

**FIG. 3.** Classic giant cell carcinoma consists of pleomorphic, multinucleated cells in an inflammatory stroma together with phenomena of emperipolesis **(A)**. A case of giant cell carcinoma with many syncytiotrophoblast-like cells in a hemorrhagic background closely mimicking a choriocarcinoma **(B)**.

taining spindle cells and/or giant cells, or a carcinoma consisting only of spindle and giant cells."[8,71,72] In agreement with a previous work by Fishback et al.[19] and with the 1999 WHO classification,[8,71,72] at least 10% of spindle and/or giant cells should be present to classify a carcinoma as PC. Following this definition, we found 58 examples of PC: 51 with an epithelial component and 7 composed only of spindle and/or giant cells. SSC is "a carcinoma consisting only of spindle-shaped tumor cells," and we found 10 examples of such an entity in our files. GCC is "a large cell carcinoma consisting only of highly pleomorphic multi and/or mononucleated tumor giant cells."[8,71,72] We were able to find only three GCC, confirming the rarity of this entity.[3,8,14,19,21,30,71,73] CS, of which we found three examples, is defined as "a malignant tumor having a mixture of carcinoma and sarcoma containing heterologous elements such as malignant cartilage, bone or skeletal muscle."[8,71,72] Finally, we found a unique example of PB, a rare "biphasic tumor

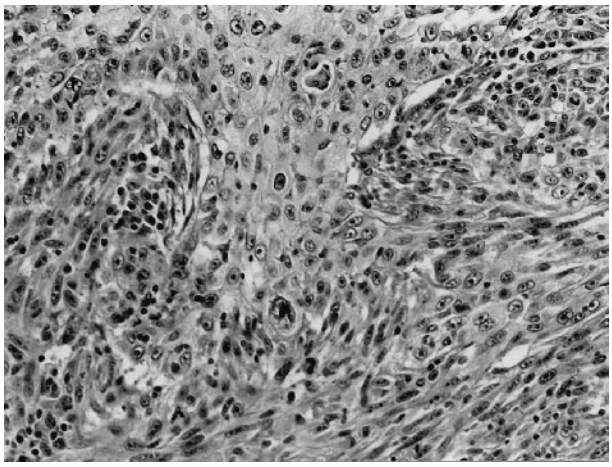

**FIG. 4.** A biphasic pleomorphic carcinoma showing an overtly carcinomatous component imperceptibly admixed with a spindle cell sarcomatoid component.

containing a primitive epithelial component that may resemble well-differentiated fetal adenocarcinoma and a primitive mesenchymal stroma."[8,71,72]

One of the most striking histologic findings in our series was the extreme heterogeneity of CPSS, not dissimilar to the heterogeneity of convential NSCLC, as documented by the classic work of Roggli et al.[60] This extreme variability of histologic presentation corresponds to a wide spectrum of differential diagnosis, which includes reactive processes, various sarcomas, and metastases from similar tumors arising in other organs.

Occasionally, CPSS may be composed of relatively bland cells in an inflammatory background, simulating a reactive process, like inflammatory pseudotumor or bronchiolitis obliterans-organizing pneumonia. These features, reported by Wick et al. as inflammatory sarcomatoid carcinoma,[75] were present in four of our cases.

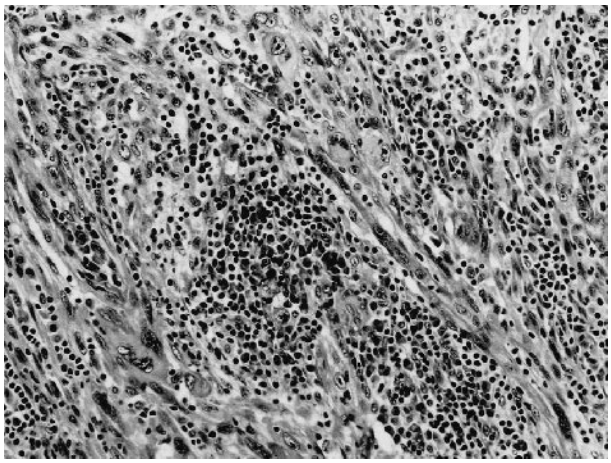

**FIG. 5.** Malignant spindle elements arranged in a storiform pattern admixed with bizarre giant cells in an inflammatory-rich stroma giving a striking resemblance to an inflammatory-type malignant fibrous histiocytoma.

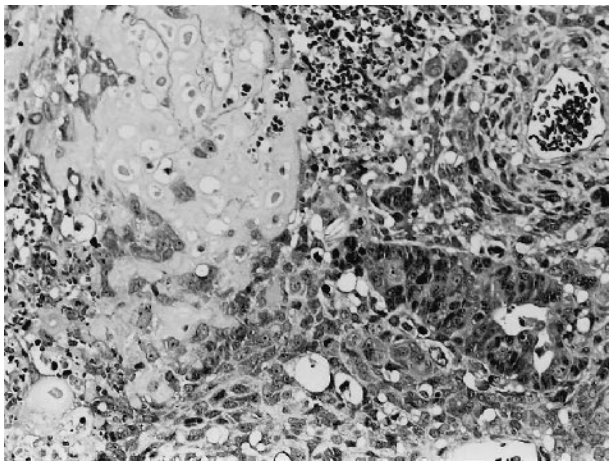

**FIG. 6.** Carcinosarcoma showing divergent chondrosarcomatous differentiation associated with a carcinomatous component.

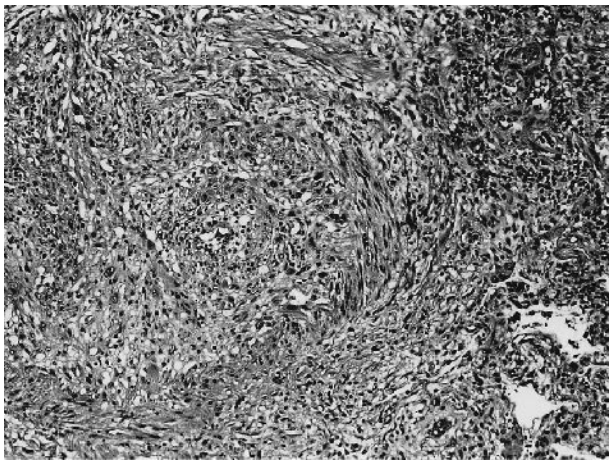

**FIG. 8.** A characteristic neoplastic luminal obliteration of pulmonary vessels by a spindle cell carcinoma.

Helpful morphologic clues of the malignant nature of the lesion are the presence of a focally moderate nuclear atypia and vascular invasion: the latter was present in 64% of our cases and was particularly frequent in SCC (9 of 10 cases).[15,76]

When a clear-cut carcinomatous component is lacking in hematoxylin and eosin, CPSS can be difficult to be differentiated from a variety of sarcomas, including fibrosarcoma, pleomorphic malignant fibrous histiocytoma, leiomyosarcoma, follicular dendritic cell sarcoma, angiosarcoma, and synovial sarcoma.[18,23,26,32,34,50,68,79] A generous sampling (at least one section per centimeter of tumor diameter) and the use of ancillary techniques, such as electron microscopy and immunohistochemistry, can be necessary to disclose the epithelial nature of the tumor.

The differential diagnosis of pulmonary CPSS with histologically identical tumors arising in other organs has not been well assessed in the literature. For this purpose

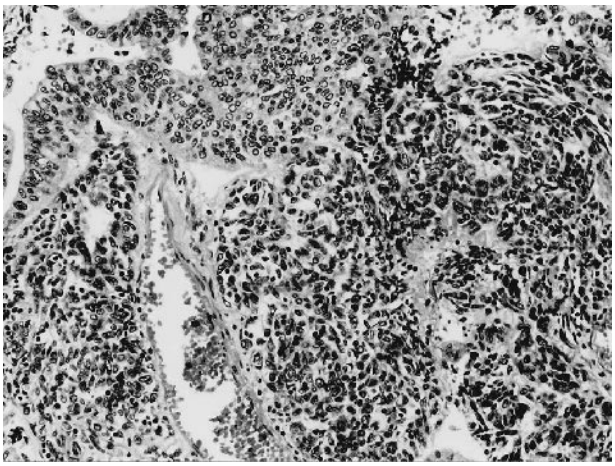

**FIG. 7.** Pulmonary blastoma displays endometrioid-like malignant glands mingled with a blastematous component.

we investigated the utility of several commercially available monoclonal antibodies, including TTF-1, CK7, CK20, and SP-A. TTF-1 immunoreactivity has been demonstrated in the majority of pulmonary ADC and small cell and large cell neuroendocrine carcinomas, whereas variable staining was reported for SqC, LCC, and carcinoids.[2,28,33,52,62,65,66] SP-A is frequently positive in pulmonary ADC but is negative in the other histotypes.[5,11,24,35,51,62] Finally, the coordinated expression of CK7 and CK20 is routinely used in trying to determine the origin of various neoplasms.[12,39,40,44,45]

To our knowledge, TTF-1, CK7, CK20, and SP-A have never been studied in pulmonary CPSS. However, similar works are reported with variable results in anaplastic carcinomas of the thyroid, an undifferentiated neoplasm sharing a close morphologic resemblance to pulmonary CPSS. Miettinen and Franssila[43] investigated 35 anaplastic thyroid carcinomas reporting TTF-1 and CK7 immunoreactivity in 2 and 24 cases, respectively, whereas Bejarano et al.[6] found TTF-1 and CK7 expression in 1 and in 0 of their 4 cases, respectively. We obtained a positive staining for TTF-1, CK7, and SP-A in the sarcomatoid (spindle and/or giant) cells of 43.1% (22 of 51), 62.7% (32 of 51), and 5.9% (3 of 51) of PC with an epithelial component, and in 55% (11 of 20), 70% (14 of 20), and 0% of carcinomas composed only of spindle and/or giant cells, respectively. The true sarcomatous component of CS and the blastematous tissue of PB did not react in any case with these antibodies. In the epithelial component of PC, TTF-1, CK7, and SP-A were positive, respectively, in 58.8% (30 of 51), 76.4% (39 of 51), and 39.2% (20 of 51) of the cases, whereas the same antibodies did not react in the epithelial component of CS. Because all tumors included in this study have been reclassified on the basis of the morphologic criteria of the WHO classification, markers for true mesenchymal differentiation have been performed just to confirm or

**TABLE 2.** *Immunoreactivity for TTF-1, Ck7, and SP-A in epithelial and sarcomatous/-oid components of pleomorphic carcinomas*

| | TTF-1 | | | | Ck7 | | | | SP-A | | | |
|---|---|---|---|---|---|---|---|---|---|---|---|---|
| Histotypes (n = 75) | 0 | 1+ | 2+ | 3+ | 0 | 1+ | 2+ | 3+ | 0 | 1+ | 2+ | 3+ |
| SCC (10) | 6 | 2 | 2 | – | 3 | 3 | 1 | 3 | 10 | – | – | – |
| GCC (3) | 1 | 1 | 1 | – | 1 | 1 | – | 1 | 3 | – | – | – |
| PC (GCC/SCC) (7) | 2 | 3 | 2 | – | 2 | 3 | – | 2 | 7 | – | – | – |
| PC (ADC+SCC) (7) | 2/3 | 1/2 | 1/2 | 3/– | –/1 | 1/4 | 3/1 | 3/1 | 2/6 | 3/1 | 2/– | – |
| PC (ADC+GCC) (3) | – | –/1 | 1/2 | 2/– | – | – | –/3 | 3/– | –/2 | 1/1 | 1/– | 1/– |
| PC (ADC+GCC/SCC) (4) | – | –/3 | 1/1 | 3/– | –/1 | –/1 | –/2 | 4/– | –/3 | 1/1 | 3/– | – |
| PC (SqC+SCC) (4) | 4/4 | – | – | – | 2/3 | 2/1 | – | – | 4/4 | – | – | – |
| PC (SqC+GCC/SCC) (8) | 8/8 | – | – | – | 5/7 | 3/1 | – | – | 8/8 | – | – | – |
| PC (LCC+SCC) (3) | –/2 | 2/– | 1/1 | – | – | –/1 | 2/2 | 1/– | 3/3 | – | – | – |
| PC (LCC+GCC) (6) | 2/4 | 2/1 | 1/1 | 1/– | 1/1 | –/2 | 1/2 | 4/1 | 4/6 | 2/– | – | – |
| PC (LCC+GCC/SCC) (9) | 3/5 | 3/2 | 2/2 | 1/– | 3/4 | 3/4 | 2/1 | 1/– | 7/9 | 2/– | – | – |
| PC (ADC/LCC+SCC) (1) | –/1 | – | 1/– | – | –/1 | – | – | 1/– | –/1 | – | 1/– | – |
| PC (ADC/LCC/GCC) (1) | – | –/1 | 1/– | – | – | –/1 | 1/– | – | 1/1 | – | – | – |
| PC (ADC/LCC+GCC/SCC) (3) | 1/1 | –/2 | 2/– | – | – | – | 1/3 | 2/– | 2/3 | 1/– | – | – |
| PC (ADC/SqC+GCC/SCC) (2) | 1/1 | –/1 | – | 1/– | 1/1 | – | –/1 | 1/– | 1/2 | 1/– | – | – |
| CS (3) | 2/3 | – | 1/– | – | 2/3 | – | 1/– | – | 3/3 | – | – | – |
| PB (1) | –/1 | – | 1/– | – | –/1 | – | – | 1/– | 1/1 | – | – | – |

Grading of reactivity: 0, negative; 1+, 1–25% of reactive cells; 2+, 26–50%; 3+, >50%; TTF-1, thyroid transcription factor-1; Ck7, cytokeratin 7; SP-A, surfactant protein-A; PC, pleomorphic carcinoma; ADC, adenocarcinoma; LCC, large cell carcinoma; SqC, squamous cell carcinoma; SCC, spindle cell carcinoma; GCC, giant cell carcinoma; CS, carcinosarcoma; PB, pulmonary blastoma.

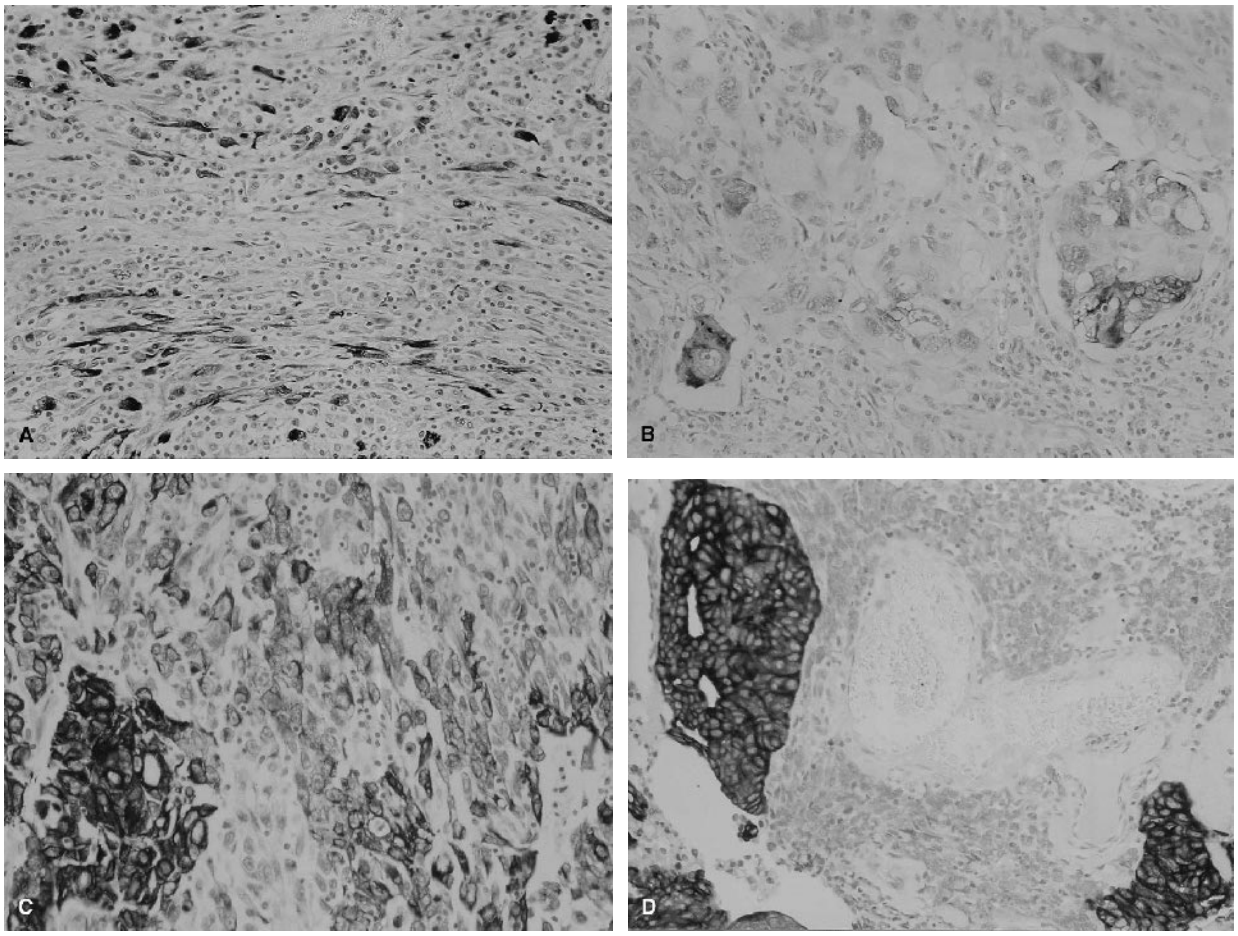


**FIG. 9.** Positive cytokeratin 7 immunostaining in spindle cell carcinoma **(A)**, in giant cell carcinoma **(B)**, and in carcinomatous and sarcomatoid components of a pleomorphic carcinoma **(C)**. Pulmonary blastoma shows positive immunostaining in the adenocarcinomatous component but not in the blastema-like tissue **(D)**.

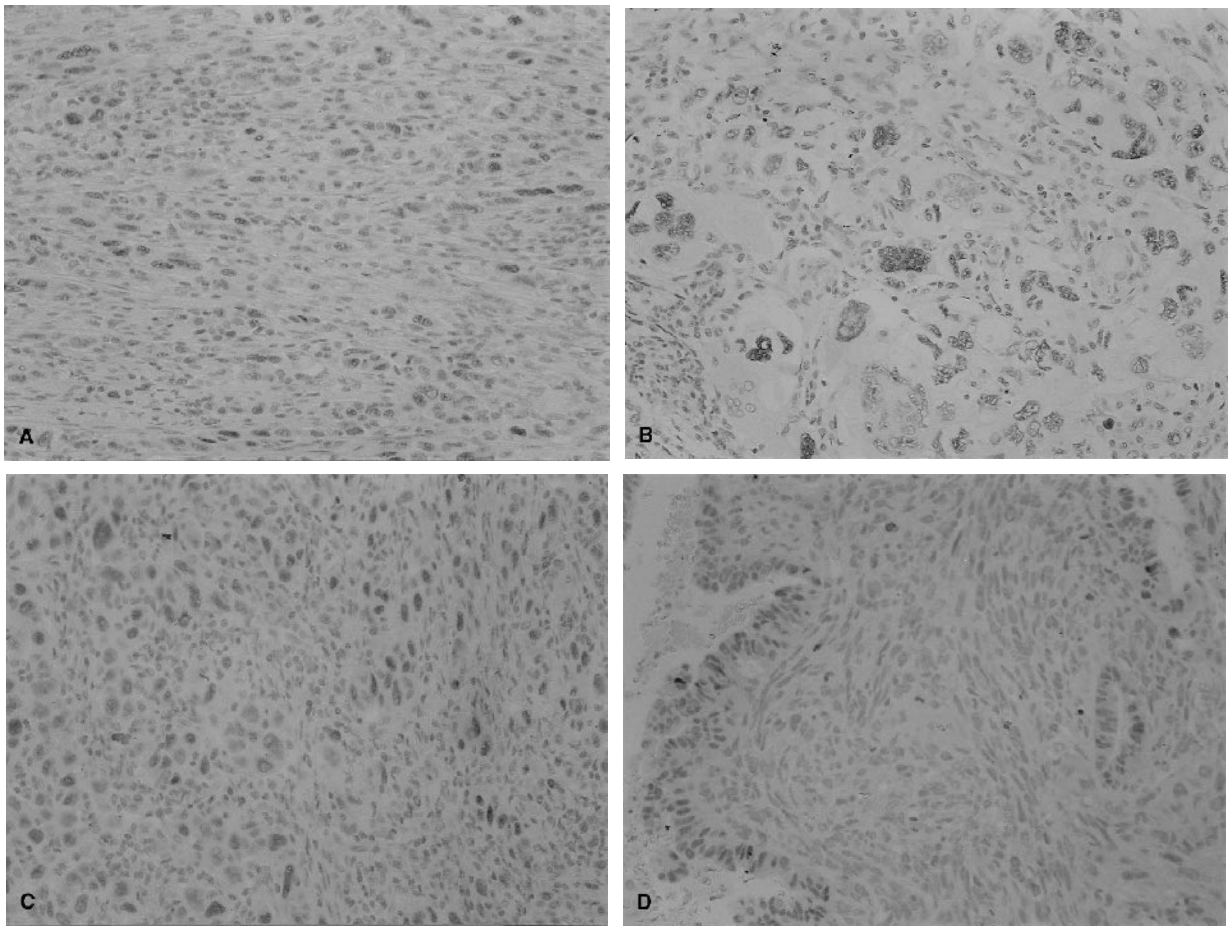


**FIG. 10.** Nuclear immunoreactivity for TTF-1 in spindle cell carcinoma **(A)**, in giant cell carcinoma **(B)**, and in carcinomatous and sarcomatoid components of a pleomorphic carcinoma **(C)**. Pulmonary blastoma displays nuclear staining in the endometrioid-like malignant glands but not in the blastematous component **(D)**.

exclude the presence of heterologous elements suspected at hematoxylin and eosin. It is therefore possible that we could have missed some heterologous elements (e.g., rhabdomyosarcomatous cells), thus reducing the real proportion of CS in our series. Positive staining for TTF-1 and CK7, but not for SP-A, was noted in the ADC component of the unique PB. CK20 was always negative.

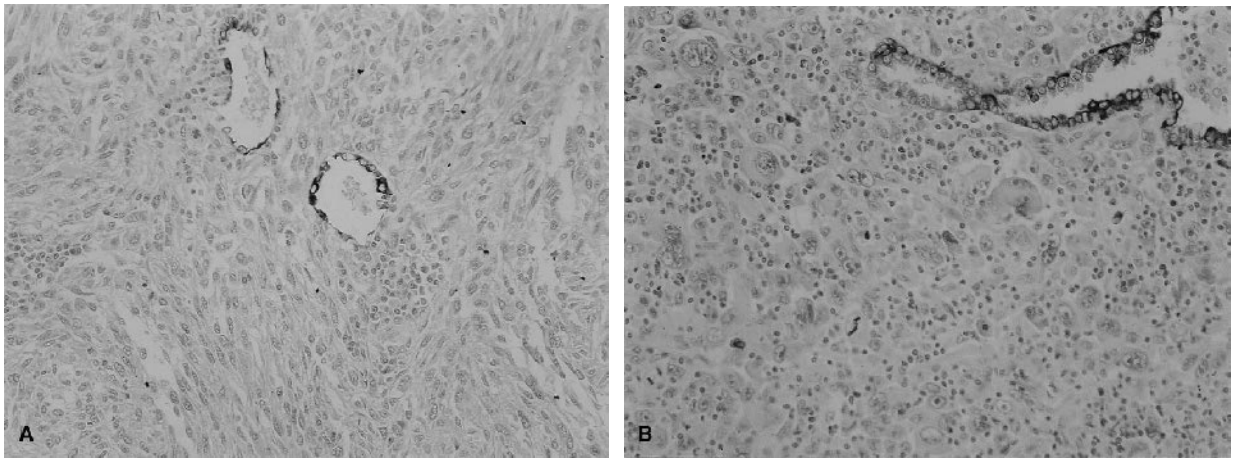


**FIG. 11.** Spindle **(A)** and giant cell carcinomas **(B)** do not stain for surfactant apoprotein-A. Note the positive internal control consisting of normal bronchiolar and alveolar structures.

Recently, Pelosi et al.[54] studied 25 PC of the lung, showing a statistically significant difference between the carcinomatous and the sarcomatoid component in the immunoreactivity for cytokeratins, epithelial membrane antigen, carcinoembryonic antigen, p21, p27, tumor suppressor gene FHIT (particularly expressed in the carcinomatous component), and vimentin, fascin, and CD34 (mainly restricted in the sarcomatoid areas): the authors concluded that this divergent differentiation between the epithelial and the sarcomatoid elements justifies a segregation of PC from conventional NSCLC. We failed to obtain the same results regarding TTF-1, SP-A, and CK7 expression. By contrast, it is noteworthy that in PC with carcinomatous and sarcomatoid cells, we obtained the same pattern of immunostaining (positive or negative) for TTF-1 and CK7 in both components in 84.3% (43 of 51) and 86.2% (44 of 51) of the cases, respectively, even if with a less degree of intensity in sarcomatoid elements.

Although this study does not have the main goal to discuss the histogenesis of CPSS, the finding of a similar immunoreactivity for CK7 and TTF-1 in the sarcomatoid and epithelial components supports the concept that these tumors should be considered as carcinomas with a divergent sarcomatoid differentiation, rather than "collision" neoplasms.[19,29,31,38,48,49,75–77] Consistent with this concept, previous studies have been demonstrated the same genetic abnormalities in microdissected areas of CPSS in both components.[16,27,70] Interestingly, our case of choriocarcinoma-like GCC reacted with both TTF-1 and CK7, supporting the hypothesis that, in the lung, this tumor is simply a variant of NSCLC. From a morphologic viewpoint, choriocarcinoma typically displays a dimorphic neoplastic population consisting of cytotrophoblastic and syncytiotrophoblastic elements, whereas, as in our case, a continuum spectrum of cellular size from medium to giant and multinucleated cells characterizes pulmonary PCs in general and GCCs in particular.[3] Considering the above finding, the well-known "burnt-out" phenomenon occurring in germinal tumors, and the possible expression of ectopic placental hormones in many nontrophoblastic malignancies, including conventional lung carcinomas, a diagnosis of primary pulmonary choriocarcinoma should be accepted only after a meticulous clinicopathologic and immunohistochemical analysis has been performed. In this setting TTF-1 seems to represent a helpful marker because we have tested five bona fide choriocarcinomas of the testis and 10 normal placentas, but staining was observed neither in cytotrophoblasts nor in syncytiotrophoblasts (unpublished observation).

CPSS is a rare tumor, prevailing in adult males. It accounts for 1.3% of all primary lung malignancies diagnosed in our institutions (75 of 5788), showing a little higher incidence rate than that reported in the classic epidemiologic study by Travis et al.[73] A possible explanation for this discrepancy is the extensive tumor sampling performed in our cases (mean of 6.5 blocks × tumor). In our series the mean age at diagnosis was 65 years, and 92% of patients were smokers. The male/female ratio we obtained (9.7:1) was higher than that reported by other authors[9,41,42,47,78] but similar to that found by Ishida et al.[31] and Pelosi et al.[54] In accordance with the literature,[10,19,21,29,31,41,42,47–49,59,67,75–78] CPSS presented in our series as a large, frequently peripheral, necrotic mass mainly involving upper lobes. The most frequent symptoms were cough and hemoptysis.

As in conventional NSCLC, stage seems to be the most important prognostic parameter. By contrast, we failed to obtain a statistically significant correlation with survival with other parameters (tumor size and location, histotype, extent of necrosis, immunohistochemical results, or lymph node involvement), as disclosed in other works.[19,47,59] The median survival from the initial diagnosis was 19 months, similar to that obtained by other authors.[10,19,21,29,41,42,78] None of the patients who died survived ≥5 years. Surgically treated CPSS at stage I seem to have a worse prognosis than conventional NSCLC.[69] Supporting this observation, 27 of 43 (63%) patients at stage I did not achieve 5-year survival, a higher percentage if compared with that reported in the classic work by Mountain.[46] However, larger series of CPSS are needed to better evaluate prognosis.

In summary, we presented the clinical, histologic, and immunohistochemical findings of 75 CPSS of the lung. As a group, pulmonary CPSS shows a quite heterogeneous morphology and probably carries a worse prognosis than conventional NSCLC; as in the latter, stage seems to be the only parameter statistically related to prognosis. Finally, we found that TTF-1 and CK7 are positive in a significant percentage of pulmonary CPSS. These antibodies may be extremely useful in supporting the pulmonary origin of a sarcomatoid carcinoma, whereas SP-A is not helpful in this specific setting. □

## Acknowledgments

The authors thank Dr. Stefania Bencini, Dr. Nicola Bellini, and Ms. Paola Manni for their skillfull technical assistance.

## REFERENCES

1. Addis BJ, Corrin B. Pulmonary blastoma, carcinosarcoma, and spindle-cell carcinoma: an immunohistochemical study of keratin intermediate filaments. *J Pathol* 1985;147:291–301.
2. Agoff NS, Lamps LW, Philip AT, et al. Thyroid transcription factor-1 is expressed in extrapulmonary small cell carcinomas but not in other extrapulmonary neuroendocrine tumors. *Mod Pathol* 2000;13:238–42.
3. Attanoos RL, Papagiannis A, Suttinont P, et al. Pulmonary giant cell carcinoma: pathologic entity or morphologic phenotype? *Histopathology* 1998;32:225–31.
4. Battifora H. Spindle-cell carcinoma: ultrastructural evidence of squamous origin and collagen production by the tumor cells. *Cancer* 1976;37:2275–82.

5. Bejarano PA, Baughman RP, Biddinger PW, et al. Surfactant proteins and thyroid transcription factor-1 in pulmonary and breast carcinomas. *Mod Pathol* 1996;9:445–52.
6. Bejarano PA, Nikiforov YE, Swenson ES, et al. Thyroid transcription factor-1, thyroglobulin, cytokeratin 7, and cytokeratin 20 in thyroid neoplasms. *Appl Immunohistochem Mol Morphol* 2000;8: 189–94.
7. Berho M, Moran CA, Suster S. Malignant mixed epithelial/mesenchymal neoplasms of the lung. *Semin Diagn Pathol* 1995;12:123–39.
8. Brambilla E, Travis WD, Colby TV, et al. The new World Health Organization classification of lung tumors. *Eur Respir J* 2001;18: 1059–68.
9. Cagle PT, Alpert LC, Carmona PA. Peripheral biphasic adenocarcinoma of the lung: light microscopic and immunohistochemical findings. *Hum Pathol* 1992;23:197–200.
10. Chang YL, Lee YC, Shih JY, et al. Pulmonary pleomorphic (spindle) cell carcinoma: peculiar clinicopathologic manifestations different from ordinary nonsmall cell carcinoma. *Lung Cancer* 2001;34:91–7.
11. Chieng DC, Cangiarella JF, Zakowski MF, et al. Use of thyroid transcription factor 1, PE-10, and cytokeratins 7 and 20 in discriminating between primary lung carcinomas and metastatic lesions in fine-needle aspiration biopsy specimens. *Cancer (Cytopathol)* 2001;93:330–6.
12. Chu PG, Wu E, Weiss LM. Cytokeratin 7 and cytokeratin 20 expression in epithelial neoplasms: a survey of 435 cases. *Mod Pathol* 2000;13:962–72.
13. Chu PG, Weiss LM. Keratin expression in human tissues and neoplasms. *Histopathology* 2002;40:403–39.
14. Colby TV, Koss M, Travis WD. Tumors of the lower respiratory tract. In: *Atlas of Tumor Pathology*, 3rd series, fascicle 13. Washington, DC: Armed Forces Institute of Pathology, 1994.
15. Colby TV. Malignancies in the lung and pleura mimicking benign processes. *Semin Diagn Pathol* 1995;12:30–44.
16. Dacic S, Finkelstein SD, Sasotomi E, et al. Molecular phatogenesis of pulmonary carcinosarcoma as determined by microdissection-based allelotyping. *Am J Surg Pathol* 2002;26:510–6.
17. Di Loreto C, Di Lauro V, Puglisi F, et al. Immunohistochemical expression of tissue specific transcription factor-1 in lung carcinoma. *J Clin Pathol* 1997;50:30–2.
18. Essary LR, Vargas SO, Fletcher CDM. Primary pleuropulmonary synovial sarcoma: reappraisal of a recently described anatomic subset. *Cancer* 2002;94:459–69.
19. Fishback NF, Travis WD, Moran CA, et al. Pleomorphic (spindle/giant cell) carcinoma of the lung: a clinicopathologic correlation of 78 cases. *Cancer* 1994;73:2936–45.
20. Folpe AL, Gown AM, Lamps LW, et al. Thyroid transcription factor-1: immunohistochemical evaluation in pulmonary neuroendocrine tumors. *Mod Pathol* 1999;12:5–8.
21. Ginsberg SS, Buzaid AC, Stern H, et al. Giant cell carcinoma of the lung. *Cancer* 1992;70:606–10.
22. Guarino M, Tricomi P, Giordano F, et al. Sarcomatoid carcinomas: pathologic and histopathogenetic considerations. *Pathology* 1996; 28:298–305.
23. Guccion JG, Rosen SH. Bronchopulmonary leiomyosarcomas and fibrosarcomas: a study of 32 cases and review of the literature. *Cancer* 1972;30:835–47.
24. Hecht JL, Pinkus JL, Weinstein LJ, et al. The value of thyroid transcription factor-1 in cytologic preparations as a marker for metastatic adenocarcinoma of lung origin. *Am J Clin Pathol* 2001; 116:483–8.
25. Hiroshima K, Ishibashi M, Ohwada H, et al. A case of adenocarcinoma of the lung with a spindle cell component. *Acta Pathol Jpn* 1992;42:841–6.
26. Hisaoka M, Hashimoto H, Iwamasa T, et al. Primary synovial sarcoma of the lung: report of two cases confirmed by molecular detection of SYT-SSX fusion gene trancript. *Histopathology* 1999; 34:205–10.
27. Holst VA, Finkelstein S, Colby TV, et al. p53 and K-ras mutational genotyping in pulmonary carcinosarcoma, spindle cell carcinoma, and pulmonary blastoma: implications for histogenesis. *Am J Surg Pathol* 1997;21:801–11.
28. Holzinger A, Dingle S, Bejarano PA, et al. Monoclonal antibody to thyroid transcription factor-1: production, characterization, and usefulness in tumor diagnosis. *Hybridoma* 1996;15:49–53.
29. Humphrey PA, Scroggs MW, Roggli VL, et al. Pulmonary carcinoma with sarcomatoid element. *Hum Pathol* 1988;19:155–65.
30. Ikura Y, Inoue T, Tsukuda H, et al. Primary choriocarcinoma and human chorionic gonadotrophin-producing giant cell carcinoma of the lung: are they independent entities? *Histopathology* 2000;36: 17–25.
31. Ishida T, Tateishi M, Kaneko S, et al. Carcinosarcoma and spindle cell carcinoma of the lung: clinicopathologic and immunohistochemical studies. *J Thorac Cardiovasc Surg* 1990;100:844–52.
32. Kaplan MA, Goodman MD, Satish J, et al. Primary pulmonary sarcoma with morphologic features of monophasic synovial sarcoma and chromosome translocation t(X;18). *Am J Clin Pathol* 1996;105:195–9.
33. Kaufmann O, Dietel M. Expression of thyroid transcription factor-1 in pulmonary and extrapulmonary small cell carcinomas and other neuroendocrine carcinomas of various primary sites. *Histopathology* 2000;36:415–20.
34. Keel SB, Bacha E, Mark EJ, et al. Primary pulmonary sarcomas: a clinicopathologic study of 26 cases. *Mod Pathol* 1999;12:1124–31.
35. Khoor A, Whitsett JA, Stahlman MT, et al. Utility of surfactant protein B precursor and TTF-1 in differentiating adenocarcinoma of the lung from malignant mesothelioma. *Hum Pathol* 1999;30: 695–700.
36. Koss MN, Hochholzer L, O'Leary T. Pulmonary blastomas. *Cancer* 1991;67:2368–81.
37. Koss MN, Hochholzer L, Frommelt AR. Carcinosarcomas of the lung: a clinicopathologic study of 66 patients. *Am J Surg Pathol* 1999;23:1514–26.
38. Krompecher E. Der drusernartige oberflachen-epitheliakrebs-carcinom epitheliale adenoides. *Beitr Pathol* 1900;28:1–41.
39. Leroy X, Copin MC, Boman F, et al. Les cytokératines 7 et 20: aide au typage des tumeurs. *Ann Pathol* 1998;18:103–9.
40. Loy TS, Calaluce RD. Utility of cytokeratin immunostaining in separating pulmonary adenocarcinomas from colonic adenocarcinomas. *Am J Clin Pathol* 1994;102:764–7.
41. Matsui K, Kitagawa M, Miwa A. Lung carcinoma with spindle cell components: sixteen cases examined by immunohistochemistry. *Hum Pathol* 1992;23:1289–97.
42. Matsui K, Kitagawa M. Spindle cell carcinoma of the lung: a clinicopathologic study of three cases. *Cancer* 1991;67:2361–7.
43. Miettinen M, Franssila KO. Variable expression of keratins and nearly uniform lack of thyroid transcription factor 1 in thyroid anaplastic carcinoma. *Hum Pathol* 2000;31:1139–45.
44. Miettinen M. Keratin 20: immunohistochemical marker for gastrointestinal, urothelial, and Merkel cell carcinomas. *Mod Pathol* 1995;8:384–8.
45. Moll R, Lowe A, Laufer J, et al. Cytokeratin 20 in human carcinomas: a new histodiagnostic marker detected by monoclonal antibodies. *Am J Pathol* 1992;140:427–47.
46. Mountain CF. Revisions of the International System for staging lung cancer. *Chest* 1997;111:1710–7.
47. Nakajima M, Kasai T, Hashimoto H, et al. Sarcomatoid carcinoma of the lung: a clinicopathologic study of 37 cases. *Cancer* 1999; 86:608–16.
48. Nappi O, Glasner SD, Swanson PE, et al. Biphasic and monophasic sarcomatoid carcinomas of the lung: a reappraisal of 'carcinosarcomas' and 'spindle cell carcinomas.' *Am J Clin Pathol* 1994;102: 331–40.
49. Nappi O, Wick MR. Sarcomatoid neoplasms of the respiratory tract. *Semin Diagn Pathol* 1993;10:137–47.
50. Nascimento AG, Unni KK. Sarcomas of the lung. *Mayo Clin Proc* 1982;6:119–23.
51. Nicholson AG, McCormick CJ, Shimosato Y, et al. The value of PE-10, a monoclonal antibody against pulmonary surfactant, in distinguishing primary and metastatic lung tumors. *Histopathology* 1995;27:57–60.
52. Ordonez NG. Thyroid transcription factor-1 is a marker of lung and thyroid carcinomas. *Adv Anat Pathol* 2000;7:123–7.
53. Ordonez NG. Value of thyroid transcription factor-1 immunostaining in distinguishing small cell lung carcinomas from other small cell carcinomas. *Am J Surg Pathol* 2000;24:1217–23.

54. Pelosi G, Fraggetta F, Pasini F, et al. Pleomorphic carcinomas (PCs) of the lung represent a spectrum of nonsmall cell cancer (NSCLC) with divergent epithelial and sarcomatous differentiation [Abstract]. *Mod Pathol* 2002;15:326.
55. Rainosek DE, Ro JY, Ordonez NG, et al. Sarcomatoid carcinoma of the lung: a case with atypical carcinoid and rhabdomyosarcomatous components. *Am J Clin Pathol* 1994;102:360–4.
56. Ramaekers F, van Niekerk C, Poels L, et al. Use of monoclonal antibodies to keratin 7 in the differential disgnosis of adenocarcinomas. *Am J Pathol* 1990;136:641–55.
57. Reis-Filho JS, Carrilho C, Valenti C, et al. Is TTF1 a good immunohistochemical marker to distinguish primary from metastatic lung adenocarcinomas? *Pathol Res Pract* 2000;196:835–40.
58. Ritter JH, Mills SE, Nappi O, et al. Angiosarcoma-like neoplasms of epithelial organs: true endothelial tumors or variants of carcinoma? *Semin Diagn Pathol* 1995;12:270–82.
59. Ro JY, Chen JL, Lee JS, et al. Sarcomatoid carcinoma of the lung: immunohistochemical and ultrastructural studies of 14 cases. *Cancer* 1992;69:376–86.
60. Roggli Vl, Voller RT, Greenberg SD, et al. Lung cancer heterogeneity: a blinded and randomized study of 100 consecutive cases. *Hum Pathol* 1985;16:569–79.
61. Saphir O, Vass A. Carcinosarcoma. *Am J Cancer* 1938;33:331–59.
62. Sheppard MN. Specific markers for pulmonary tumors. *Histopathology* 2000;36:273–6.
63. Sobin LH, Wittekind CH, eds. *UICC TNM Classification of Malignant Tumors*, 5th ed. New York. John Wiley and Sons, 1997.
64. Stackhouse EM, Harrison, EG Jr, Ellis FH Jr. Primary mixed malignancies of lung: carcinosarcoma and blastoma. *J Thorac Cardiovasc Surg* 1969;57:385–99.
65. Sturm N, Rossi G, Lantuejoul S, et al. Expression of thyroid transcription factor-1 in the spectrum of neuroendocrine cell lung proliferations with special interest in carcinoids. *Hum Pathol* 2002; 33:175–82.
66. Sturm N, Lantuejoul S, Laverriere MH, et al. Thyroid transcription factor-1 (TTF-1) and cytokeratin 1, 5, 10, 14 (34βE12) expression in basaloid and large cell neuronedocrine carcinomas of the lung. *Hum Pathol* 2001;32:918–25.
67. Suster S, Huszar M, Herczeg E. Spindle-cell carcinoma of the lung: immunocytochemical and ultrastructural study of a case. *Histopathology* 1987;11:871–8.
68. Suster S. Primary sarcomas of the lung. *Semin Diagn Pathol* 1995; 12:140–57.
69. Tanoue LT, Ponn RB. Therapy for stage I and stage II nonsmall cell lung cancer. *Clin Chest Med* 2002;23:173–90.
70. Thompson L, Chang B, Barsky SH. Monoclonal origins of malignant mixed tumors (carcinosarcomas): evidence for a divergent histogenesis. *Am J Surg Pathol* 1996;20:277–85.
71. Travis WD. Pathology of lung cancer. *Clin Chest Med* 2002;23: 65–81.
72. Travis WD, Colby TV, Corrin B, et al. In collaboration with Sobin LH and Pathologists from 14 countries. World Health Organization International Histological Classification of Tumors. *Histological Typing of Lung and Pleural Tumors*, 3rd ed. Berlin: Springer-Verlag, 1999.
73. Travis WD, Travis LB, Devesa SS. Lung cancer. *Cancer* 1995;75: 191–202.
74. Tsubota YT, Kagawaguchi T, Hoso T, et al. A combined small cell carcinoma and spindle cell carcinoma of the lung: report of a unique case with immunohistochemical and ultrastructural studies. *Am J Surg Pathol* 1992;16:1108–15.
75. Wick MR, Ritter JH, Humphrey PA. Sarcomatoid carcinomas of the lung: a clinicopathologic review. *Am J Clin Pathol* 1997;108: 40–53.
76. Wick MR, Ritter JH, Nappi O. Inflammatory sarcomatoid carcinoma of the lung: report of three cases and clinicopathologic comparison with inflammatory pseudotumors in adult patients. *Hum Pathol* 1995;26:1014–21.
77. Wick MR, Swanson PE. Carcinosarcomas: current perspectives and an historical review of nosologic concepts. *Semin Diagn Pathol* 1993;10:118–27.
78. Xu X, Yin H, Meng K, et al. Pathological study of the pleomorphic carcinoma of the lung. *Zhonghua Bing Li Xue Za Zhi* 2000;29: 424–7.
79. Zeren EH, Moran CA, Suster S, et al. Primary pulmonary sarcomas with features of monophasic synovial sarcoma: a clinicopathologic, immunohistochemical, and ultrastructural study of 25 cases. *Hum Pathol* 1995;26:474–80.